

CASOS CLÍNICOS

Inhaled anesthetic sedation, an alternative to the scarcity of traditional sedatives: a case report

Sedación anestésica inhalada, una alternativa a la escasez de los
sedantes tradicionales: reporte de un caso

Recibido: 15-06-2022 **Aceptado:** 07-09-2022 **Publicado:** 30-12-2022

DOI: <https://doi.org/10.47464/MetroCiencia/vol30/4/2022/77-84>

Revista **MetroCiencia**
Volumen 30, Número 4, 2022
ISSNp: 1390-2989 **ISSNe:** 2737-6303
Editorial Hospital Metropolitano

Inhaled anesthetic sedation, an alternative to the scarcity of traditional sedatives: a case report

Sedación anestésica inhalada, una alternativa a la escasez de los sedantes tradicionales: reporte de un caso

Jorge Luis Vélez-Páez^{1,2*}, Fernando Esteban Jara¹, Esteban Ochoa¹, Verónica Guerrero¹, Estefanía Irigoyen¹, Hernán Quintero¹, Eduardo Vásconez³, Pablo A. Santillán⁴, Esteban Ortiz-Prado³

ABSTRACT

Critically ill patients often require multi-purpose sedation in intensive care units. Drugs used for this purpose can be administered intravenously and less commonly by inhalation. The COVID-19 pandemic has currently brought us several consequences, such as the depletion of pharmacological resources, which leads us to the non-routine use of alternatives to achieve the same sedation goals, even with fewer adverse effects and better results terms of the outcome of its disease. Volatile anesthetics have been considered as an option, the same ones that are administered through the AnaConDa inhalation precipitate system. We present a case of a patient with a confirmed diagnosis of COVID-19, who develops secondary severe ARDS and a subsequent need for deep sedation, providing it with a volatile anesthetic (sevoflurane) using the AnaConDa system.


Keywords: AnaConDa, volatile anesthetic, COVID-19.

RESUMEN

Los pacientes críticos a menudo requieren sedación polivalente en las unidades de cuidados intensivos. Los fármacos utilizados para este fin pueden administrarse por vía intravenosa y, con menos frecuencia, por inhalación. La pandemia de COVID-19 en la actualidad nos ha traído varias consecuencias, como el agotamiento de los recursos farmacológicos, lo que nos lleva al uso no rutinario de alternativas para lograr los mismos objetivos de sedación, incluso con menos efectos adversos y mejores resultados en cuanto a la evolución de su enfermedad. Se han considerado como opción los anestésicos volátiles, los mismos que se administran a través del sistema de inhalación de precipitados AnaConDa. Presentamos el caso de un paciente con diagnóstico confirmado de COVID-19, que desarrolla SDRA severo secundario y posterior necesidad de sedación profunda, proporcionándole un anestésico volátil (sevoflurano) mediante el sistema AnaConDa.

Palabras clave: AnaConDa, anestésico volátil, COVID-19.

Jorge Luis Vélez-Páez

 <https://orcid.org/0000-0002-6956-4475>

Fernando Esteban Jara

 <https://orcid.org/0000-0003-2132-7187>

Esteban Ochoa

 <https://orcid.org/0000-0001-6981-553X>

Verónica Guerrero

 <https://orcid.org/0000-0003-3762-1890>

Estefanía Irigoyen

 <https://orcid.org/0000-0002-4904-1124>

Hernán Quintero

 <https://orcid.org/0000-0001-6929-9774>


Eduardo Vásconez

 <https://orcid.org/0000-0003-4573-6217>

Pablo A. Santillán

 <https://orcid.org/0000-0001-6240-7461>

Esteban Ortiz-Prado

 <https://orcid.org/0000-0002-1895-7498>

1. Unidad de Cuidados Intensivos; Hospital Pablo Arturo Suárez; Quito, Ecuador.
2. Facultad de Medicina; Universidad Central del Ecuador; Quito, Ecuador.
3. Primer Grupo de Investigación; Universidad de las Américas; Quito, Ecuador.
4. Departamento de Anestesiología; Centro Clínico Atlas; Quito, Ecuador.



Usted es libre de:

Compartir — copiar y redistribuir el material en cualquier medio o formato.

Adaptar — remezclar, transformar y construir a partir del material para cualquier propósito, incluso comercialmente.

*Correspondencia: jlvelez@uce.edu.ec

INTRODUCTION

Sedation in critically ill patients undergoing invasive mechanical ventilation reduces anxiety and agitation, facilitates an adequate ventilatory coupling, and allows invasive procedures. Many drugs are used to reach this end, among them midazolam and propofol; however, these drugs have pharmacological characteristics that keep them from being an ideal sedative since they must have a rapid onset and displacement, not alter hemodynamics, avoid their accumulation with prolonged use, and be eliminated relatively quickly when suspended^{1,2}.

COVID-19 can manifest as severe pneumonia that progresses to acute respiratory distress syndrome (ARDS), which in many cases requires mechanical ventilation and deep sedation. The exponentially increasing number of critical cases have saturated even the most robust health systems and have depleted the world's pharmacological reserves of sedative drugs, leaving us, on several occasions, without therapeutic alternatives^{3,4}. Volatile anesthetics (sevoflurane, isoflurane) have constituted an important part of general anesthesia in operating rooms; however, they have been used very little in Intensive Care Units. Considering that the pathophysiology of COVID-19 is directly related to a strong pro-inflammatory immune response, it has been seen that sedation with volatile inhalation agents can reduce the severity and progression of the disease and become an alternative by avoiding many of the side effects that are associated

with the use of intravenous sedatives³⁻⁵. In 2005, the AnaConDa device, which stands for Anesthetic Conserving Device (ACD) (*Figure 1*), was marketed allowing the administration of inhalational drugs with standard ventilators in critical care units. It consists of a modified heat and humidity exchanger filter, which, inserted in the patient's ventilatory circuit, allows the administration of halogenated agents through a vaporization chamber connected to a syringe with the liquid anesthetic^{1,6,7}.

Some of the advantages of inhalation sedation over intravenous sedation are⁸:

- It does not produce respiratory depression.
- It does not decrease intestinal motility.
- Allows planned extubation.
- Allows sedation windows.
- Easy monitoring and dosing.
- Little accumulation.
- Liver metabolism less than 5%, without active metabolites.
- Independent of kidney and liver function.
- It does not need a venous route.
- Bronchodilator effect of some anesthetic gases, such as sevo and isoflurane.

Inhalation sedation use has several indications and contraindications⁹, which are summarized in *Table 1*.

Table 1. Indications and Contraindications of inhalation sedation.

Indications	Contraindications
Deep sedation in which you want to avoid the side effects of the infusion of Midazolam or Propofol.	Hypersensitivity to the active principle or to any of its excipients.
Difficult sedation (inability to maintain target RASS at -3 to -5).	Known or suspected genetic susceptibility to malignant hyperthermia.
Very prolonged sedation, after 5 days of deep sedation with Midazolam and / or Propofol, and the patient must still remain with deep sedation.	Significant broncho-pleural fistula.

Need for daily neurological evaluation.	Muscular dystrophy.
Status epilepticus, requiring deep sedation.	Indication of light sedation that can be easily achieved with drugs.
Neuro and cardioprotection after recovered cardiac arrest requiring sedation for any reason.	Relative Contraindications are considered liver failure.
In ARDS that requires deep sedation, which is not achieved with the maximum doses of the usual sedatives.	Kidney failure, head injury, or seizures.

The case of a patient with a confirmed diagnosis of COVID-19 is presented, who develops severe ARDS with subsequent need for deep sedation, refractory to traditional drugs, with a good response to a volatile anesthetic (Sevofluorane) with use of the AnaConDa system.

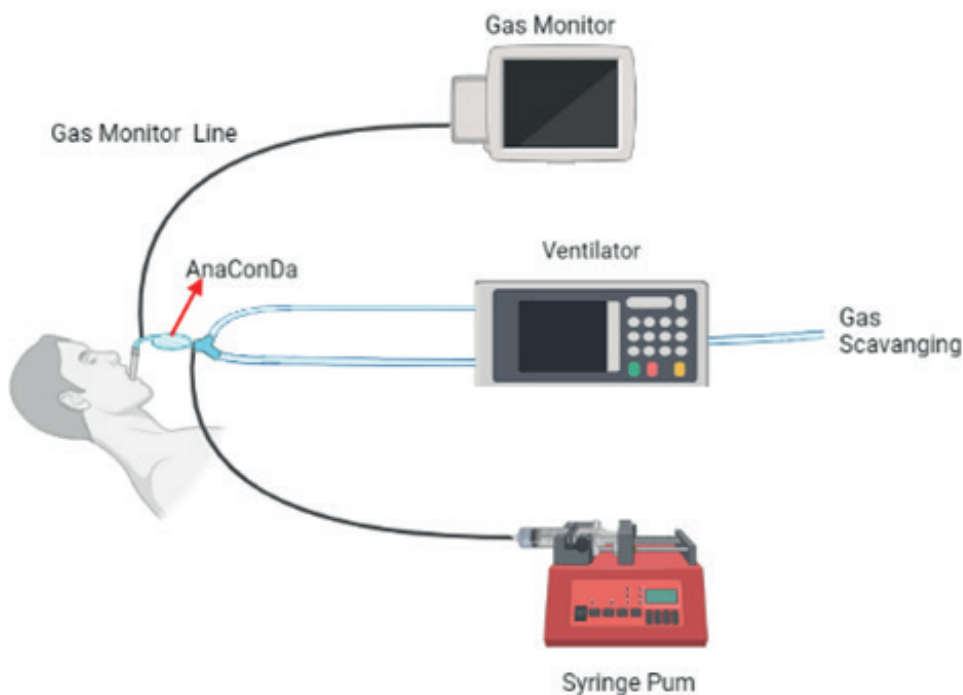


Figure 1. Anaesthesia Conserving Device

CLINICAL CASE

50-year-old Hispanic male, without significant comorbidity. He presented after 14 days of headache, rhinorrhea, and general malaise progressing to dyspnea. He was admitted with tachycardia of 130 beats per minute, tachypnea of 40 breaths per minute, use of accessory muscles, oxygen saturation of 74% in ambient air and $\text{PaO}_2/\text{FiO}_2$ ratio of 84. Non-invasive mechanical ventilation was poorly tolerated, therefore invasive mechanical ventilatory support was started in the prone position. The chest ra-

diograph showed diffuse bilateral interstitial alveoli infiltrates (**Figure 2**). He was admitted to the ICU, under the effects of sedoanalgesia and a muscle relaxant based on remifentanyl at 14 mcg/kg/h, propofol at 5 mg/kg/h, and rocuronium bromide at 0.12 mg/kg/h, respectively; the prone position was maintained. He presented shock with a mean arterial pressure of 55 mmHg and a heart rate of 48 beats per minute, which warranted management with norepinephrine-type vasopressor support at 0.08 mcg/kg/min, classifying it as a pharmacological distributive shock.

In the laboratory analysis as relevant findings, leukocytes of 12.80 (NV: 4.29 - 9.42), neutrophils 88.8% (NV: 55 - 65%), interleukin 6 (IL-6) 669.5 (NV: 0.0 - 3.4), ferritin were found 830.1 (NV: 10-291) and D-dimer 870.9 (NV: 45-500) (*Table 2*).

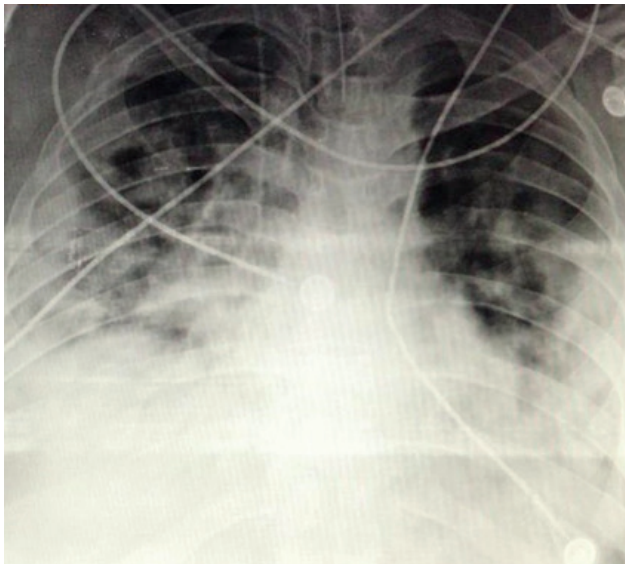


Figure 2. Anteroposterior chest radiograph showing diffuse alveolo-interstitial infiltrates.

Table 2. Laboratory results.

Exams	Outcome	Normal value
Leukocytes	12.8	4.29 - 9.42
Neutrophils	88.8%	55 - 65%
Interleukin 6	669.5	0.0 - 3.4
Ferritin	830.1	10 - 291
D-dimer	870.9	45 - 500

In the ICU, he developed tolerance to the sedative effect of propofol, for which the infusion was withdrawn and sevoflurane was started using AnaConDa. Monitoring was carried out employing the bispectral index (BIS) with objectives of 40 to 60 and the dose was titrated according to the patient's response. The initial dose on the first day of hospitalization was 14 ml/h, obtaining a BSI of 42 and a minimum alveolar concentration (MAC) of 0.9%, achieving goals of deep sedation RASS -4 or -5. On day 2, the infusion of the muscle relaxant was suspen-

ded and remifentanyl infusion was started at a dose of 7.7 mcg/kg/h, thereby reducing the dose of sevoflurane, maintaining a RASS -5 and BIS 50. For day 3 and after meeting oxygenation targets, the patient was placed in the supine position and the strategy was changed to intravenous sedation (midazolam), which was progressively increased to a dose of 0.2 mg/kg/h with a concomitant decrease in sevoflurane until his definitive retirement (*Table 3*).

During his hospital stay, the patient did not develop delirium or renal failure and the vasopressor dose was reduced until it was withdrawn within 24 hours, maintaining hemodynamic stability at all times. Successful extubation was achieved 48 hours later and subsequent discharge to the hospital ward with oxygen support at low flow through a nasal cannula (2 L/min).

DISCUSSION

The global shortage of intravenous sedatives and neuromuscular blocking agents (benzodiazepines, opioids, propofol), has become a problem for the provision of care of critical patients during the COVID-19 pandemic¹. Evidence indicates that inhaled agents such as isoflurane and sevoflurane offer sedation, muscle relaxation, and may be beneficial at low doses due to their lung clearance, anti-inflammatory, bronchodilator effects in the airways, lungs, and vascular beds, also taking into account They do not have a great analgesic effect and are therefore co-administered with intravenous opioids, in addition, they shift the hemoglobin dissociation curve to the right, increase the release of oxygen from hemoglobin to the tissues, and improve tissue oxygenation^{1,3,10}. Volatile agents reduce macrophage levels in the bronchial alveolar fluid, therefore, they also reduce the release of TNF, IL-6, IL-1, monocyte chemoattractant protein-1 (MCP-1), decrease neutrophilic adhesion and production of reactive oxygen species

Table 2. Sedoanalgesia dose and neurological monitoring using the AnaConDa system.

	Day 1	Day 2	Day 3
Drug and dosage	Remifentanil 14 ml / h	Sevoflurane 10 ml/h	Hour 1: Sevoflurane 10 ml/h, Remifentanil 7.7 mcg/kg/h and Midazolam 0.05 mg/kg/h
	Propofol 5 mg/kg/ h	Remifentanil 7.7 mcg/kg/h	Hour 3: Sevoflurane 5 ml/h, Remifentanil 7.7 mcg/kg/h and Midazolam 0.12 mg/kg/h
	Rocuronium 0.12 mg/kg/h		Hour 5: Midazolam 0.2 mg/kg/h and Remifentanil 7 mcg/kg/h
	Norepinephrine 0.08 mcg / kg / min		
RASS* Range	-4, -5	-4, -5	Hora 1: RASS -4 Hora 3: RASS -3 Hora 5: RASS -5
BSI* Range	42 – 48	50 – 56	Hora 1: BSI 52 Hora 3: BSI 67 Hora 5: BSI 46
MAC*	0.9%	0.8%	Hora 1: MAC 0.8% Hora 3: MAC 0.4% Hora 5: MAC -----

*RASS: Richmond Agitation Sedation Scale, *BSI: Bispectral Index *MAC: Minimum Alveolar Concentration.

giving rise to a powerful inhibitory effect of pro-inflammatory cytokines and a stimulating effect of anti-inflammatory cytokines, in the same way, it significantly inhibits platelet aggregation^{3,5}.

Prolonged use of volatile agents demonstrated good safety with hemodynamic stability, absence of liver and kidney toxicity, and less delirium, compared to classic intravenous agents. In addition, it facilitates synchrony with the ventilator, prone strategy, and extracorporeal oxygenation therapy (ECMO) with deeper levels of sedation. Volatile anesthetics, due to their low metabolism and solubility in blood, avoid tolerance or addiction phenomena, allowing a faster awakening compared to conventional intravenous sedatives such as propofol or midazolam, they shorten the awakening time by 80 minutes and extubation by 196 minutes. Adverse effects are very rare but can include nephrogenic diabetes insipidus, malignant hyperthermia, allergy, and hepatitis^{3,10,11}. Several authors have recommended that it is important to maintain deep sedation for

patients with COVID-19 who are admitted to mechanical ventilation to minimize aerosolization¹², however, the requirements are high, currently, sedative drugs are in short supply. alternatively, inhalation sedation with its previously described ones, the study carried out by Flinspach et al.⁴ highlighted that there was no liver and kidney toxicity. The study by Jabaudon et al.¹³ who compared sevoflurane vs midazolam for sedation in ARDS showed that patients who used inhaled sevoflurane improved oxygenation and decreased levels of endothelial markers compared to sedation with midazolam. However, concerning COVID-19, at the same time that it was shown to decrease the inflammatory response and platelet aggregation, it was also associated with adverse effects such as immune dysfunction in cases of sepsis and diabetes insipidus^{10,11}.

Currently, the management of sedation in COVID-19 patients is based on standard guidelines for intensive care and on the experience of treating patients with "classic" ARDS. There are insufficient studies on the

impact of volatile sedation on the pathophysiology of the disease. COVID-19, but it has been seen that it could be beneficial³. In the present clinical case, the administration of sevoflurane in continuous infusion into the inhalation precipitate system (AnaConDa) was indicated due to tolerance to traditional sedatives, with this it was evidenced that our patient presented better ventilatory coupling in the prone position, even without requiring treatment with neuromuscular relaxants, in addition to achieving greater hemodynamic stability and no side effects; delirium was not evidenced and there was no need to add a second sedative drug to achieve the stated sedation goals¹⁴. We consider this system useful especially when there is difficulty in adapting patients to the mechanical ventilator and in those cases in which very high doses of sedation are required. Their pharmacokinetics and pharmacodynamics make them an attractive option for sedation in the ICU, probably improving the time of extubation and discharge from intensive care. For all these reasons, the use of this sedation modality is proposed, being a valid and effective option.

CONCLUSIONS

Sedation in critically ill patients is a crucial issue, the global shortage of intravenous sedatives and neuromuscular blocking agents has become a problem for the provision of care of critical patients during the COVID-19 pandemic. Evidence indicates that the Inhaled agents such as isoflurane and sevoflurane offer sedation, muscle relaxation, and maybe beneficial at low doses. However, there are still no large studies that conclusively demonstrate the benefit of these drugs in important outcomes such as mortality. At the moment, sedation with volatile anesthetics can be considered an appropriate alternative in specific patients, but it is costly compared to traditional sedatives.

Contribución de los autores

- a) Concepción y diseño del trabajo: JV, EOP
- b) Recolección/obtención de resultados: JV, FJ, EO, VG, EI, HQ, EV, PS, EOP
- c) Análisis e interpretación de datos: JV, EOP
- d) Redacción del manuscrito: JV, EOP
- e) Revisión crítica del manuscrito: JV, FJ, EO, VG, EI, HQ, EV, PS, EOP
- f) Aprobación de su versión final: JV, EOP
- g) Aporte de pacientes o material de estudio: JV, FJ, EO, VG, EI, HQ, EV, PS, EOP
- h) Obtención de financiamiento: no aplica
- i) Asesoría estadística: no aplica
- j) Asesoría técnica o administrativa: JV, EOP
- k) Otras contribuciones (búsqueda bibliográfica): JV, FJ, EO, VG, EI, HQ, EV, PS, EOP

Conflicto de intereses

Los autores declararon no tener ningún conflicto de interés personal, financiero, intelectual, económico y de interés corporativo con el Hospital Metropolitano y los miembros de la revista MetroCiencia.

Bibliografía

1. **López-Ramos JM, Gómez-Sainz JJ, Manzano-Canalechevarría A, Aguilera-Celorrío L.** Sevoflurano como coadyuvante en la sedación durante ventilación mecánica en pacientes médicos de unidad de cuidados intensivos: resultados preliminares en una serie de casos. *Rev Colomb Anesthesiol.* 2016 Jan 1;44(1):52-7.
2. **Misra S, Koshy T.** A review of the practice of sedation with inhalational anaesthetics in the intensive care unit with the AnaConDa® device. *Indian J Anaesth.* 2012 Jan 11;56(6):518.

3. **Suleiman A, Qaswal AB, Alnouti M, Yousef M, Suleiman B, Jarbeh ME, et al.** Sedating Mechanically Ventilated COVID-19 Patients with Volatile Anesthetics: Insights on the Last-Minute Potential Weapons. *Sci Pharm.* 2021 Mar;89(1):6.
4. **Flinspach AN, Zacharowski K, Ioanna D, Adam EH.** Volatile Isoflurane in Critically Ill Coronavirus Disease 2019 Patients—A Case Series and Systematic Review. *Crit Care Explor* [Internet]. 2020 Oct [cited 2021 May 29];2(10). Available from: <https://www.ncbi.nlm.nih.gov/pmc/articles/PMC7587445/>
5. **Kim HY, Lee JE, Kim HY, Kim J.** Volatile sedation in the intensive care unit: A systematic review and meta-analysis. *Medicine (Baltimore).* 2017 Dec;96(49):e8976.
6. **Peyro R, Soro M, Aldecoa C, Valia J, Ramos F, Acosta F, et al.** Protocolo-SCC-versión-final.pdf [Internet]. 2010 [cited 2021 May 29]. Available from: <https://anestesiario.org/WP/uploads/2011/01/Protocolo-SCC-versi%C3%B3n-final.pdf>
7. **Blondonnet R, Quinson A, Lambert C, Audard J, Godet T, Zhai R, et al.** Use of volatile agents for sedation in the intensive care unit: A national survey in France. *PLOS ONE.* 2021 Apr 15;16(4):e0249889.
8. **Cuesta AP, Llorente de la Fuente AM.** Sedación inhalatoria en cuidados intensivos. *An Pediatría Contin.* 2014 May 1;12(3):142–6.
9. **Caballero J, Garcia M, Gimenez C.** PROTOCOLO-DE-SEDACIÓN-INHALATORIA-SEMICYUC-v.2.pdf [Internet]. 2020 [cited 2021 Jun 4]. Available from: <https://semicyuc.org/wp-content/uploads/2020/05/PROTOCOLO-DE-SEDACION%CC%81N-INHALATORIA-SEMICYUC-v.2.pdf>
10. **Jerath A, Ferguson ND, Cuthbertson B.** Inhalational volatile-based sedation for COVID-19 pneumonia and ARDS. *Intensive Care Med.* 2020 Aug 1;46(8):1563–6.
11. **Nieuwenhuijs-Moeke GJ, Jainandunsing JS, Struys MMRF.** Sevoflurane, a sigh of relief in COVID-19? *Br J Anaesth.* 2020 Aug 1;125(2):118–21.
12. **Marini JJ, Gattinoni L.** Management of COVID-19 Respiratory Distress. *JAMA.* 2020 Jun 9;323(22):2329.
13. **Jabaudon M, Boucher P, Imhoff E, Chabanne R, Faure J-S, Roszyk L, et al.** Sevoflurane for Sedation in Acute Respiratory Distress Syndrome. A Randomized Controlled Pilot Study. *Am J Respir Crit Care Med* [Internet]. 2017 Mar 15 [cited 2021 Jun 21]; Available from: <https://www.atsjournals.org/doi/10.1164/rccm.201604-0686OC>
14. **Tardío-Flores RA, Sejas-Clavijó J, Castellón-Sejas V, Bustamante C, Orozco-Cadima A.** Utilidad del índice bispectral en la monitorización de la conciencia durante la anestesia general. *Rev Científica Cienc Médica.* 2010 Dec;13(2):69–72.

Cómo citar: Vélez-Páez J, Jara F, Ochoa E, Guerrero V, Irigoyen E, Quintero H, Vásconez E, Santillán P, Ortiz-Prado E. Inhaled anesthetic sedation, an alternative to the scarcity of traditional sedatives: a case report. *MetroCiencia* [Internet]. 30 de diciembre de 2022; 30(4):77-84. Disponible en: <https://doi.org/10.47464/MetroCiencia/vol30/4/2022/77-84>